

## ROTATIONAL MALALIGNMENT AFTER INTRAMEDULLARY FIXATION OF TROCHANTERIC FRACTURES

Amalendu M R<sup>1</sup>, Shajimon Samuel<sup>2</sup>, Rahul Sreenivasan Thokaloath<sup>3</sup>

<sup>1</sup>Junior Resident, Department of Orthopaedics, Government Medical College, Kottayam, Kerala, India

<sup>2</sup>Associate Professor, Department of Orthopaedics, Government Medical College, Kottayam, Kerala, India

<sup>3</sup>Assistant Professor, Department of Orthopaedics, Government Medical College, Kottayam, Kerala, India

Received : 31/03/2024  
Received in revised form : 24/06/2024  
Accepted : 10/06/2024

**Keywords:** Trochanteric Fracture, Proximal Femoral Nailing, Femoral Rotational Malalignment, Fluoroscopy, Computed Tomography Scan.

Corresponding Author:  
**Dr. Shajimon Samuel,**  
Email: drshajimon1972@gmail.com

DOI: 10.47009/jamp.2024.6.3.210

Source of Support: Nil,  
Conflict of Interest: None declared

*Int J Acad Med Pharm*  
2024; 6 (3); 1025-1035



### Abstract

**Background:** To evaluate the severity of femoral malrotation after nailing of trochanteric fractures and to assess various factors affecting post operative torsional alignment. **Materials and Methods:** Observational study conducted among 71 cases of intertrochanteric fractures with intramedullary fixation by proximal femoral nailing. Once the patients were pain-free and comfortable, postoperative CT of pelvis and knee joint taken and compared for rotational alignment against the normal opposite side. Measurements were done by technique described by Jeanmart L et al. The rotational difference of <100 in comparison to the normal side was considered as grade I malrotation, 100- 150 as grade II malrotation and >150 as grade III malrotation. Data was entered in Microsoft excel and analyzed using IBM SPSS Statistics for Windows, Version 20.0. Armonk, NY: IBM Corp. IBM Corp. Categorical variables were expressed as frequency (percentage) and continues variables were expressed in mean and standard deviation. **Result:** The mean anteversion on the normal side was 15.76 degrees. The mean anteversion on the operated side was 19.87 degrees. The mean rotational malalignment was 12.18 degrees; there was internal rotational deformity in 49 cases (69%) and external rotational deformity in 22 cases (31%) with Grade III malrotation in 15 (21.13%) cases. **Conclusion:** Rotational malalignment postoperatively is frequently present and needs to be corrected intraoperatively by improving assessment methods.

## INTRODUCTION

Intertrochanteric femur fractures are commonly treated by orthopedic surgeons in their daily practice. Their numbers are increasing due to increase in the elderly population. The main goal of management is early safe and secure fracture fixation to enable early mobilization and eventually return to better quality of life.<sup>[1]</sup> The method of fixation that is currently evolving is the cephalomedullary nail. This technique has its advantages; lesser operating time, less blood loss, improved anatomical alignment, early load bearing even in the unstable fracture pattern and fewer days in hospital.<sup>[2,3]</sup> The outcome of surgical fixation is more determined by surgical techniques and quality of intraoperative reduction than implant designs. Assessment of quality of reduction is easy in frontal and sagittal plane but challenging to assess rotational alignment in horizontal plane due to limitation of intra operative fluoroscopy. Possible complications during intramedullary nailing are; iatrogenic fracture of lateral wall, implant breakage,

screw cut in or screw cut out and rotational malalignment. Rotational malalignment is one of the most underrecognized complication of intramedullary nailing and also the most challenging to detect radiographically and clinically. It is often missed or neglected.<sup>[4]</sup> Incidence of rotational malalignment vary from 17 to 35%.<sup>[5]</sup> Rotational malalignment or torsional deformity of the femur is defined as a difference of femoral anteversion between the injured and uninjured leg. Rotational malalignment can be measured by physical examination, radiography and CT scan. Measurements of anteversion angle by CT are considered gold standard.<sup>[6,7]</sup> Many studies are available for diaphyseal femur fractures regarding incidence of rotational malalignment and intra operative techniques to reduce the same but less literature available for intertrochanteric femur fractures. Stable fractures are generally reduced well with closed means under image/C-arm control. Comminution increases instability and reduces fracture apposition surfaces, which warrants

additional means of reduction and maintenance of fracture reduction. These fractures occur due to uncontrolled external rotation. Anterior cortex breaks first in tension and followed by posterior cortex in compression causing its comminution. During open reduction assisted with fluoroscopy palpatory method for anterior cortical reduction is used to assess adequacy of reduction. Anterior cortical reduction methods in isolation can misguide the overall 360-degree reduction of intertrochanteric fractures. This assessment method is further compromised as comminution increases. In literature the problem of femoral torsion (rotational malalignment) pertaining to unstable femur diaphyseal fractures has been studied but there is no literature available, to our knowledge which guides to reduce intra operative malrotation in intertrochanteric femur fractures. In this study we report occurrence and grading of malrotation femur occurred when trochanteric fractures were treated by proximal femoral nailing, at the department of orthopaedics, Government Medical College, Kottayam during the period of study.

## MATERIALS AND METHODS

Observational study was conducted in a tertiary care hospital, Government Medical College, Kottayam among 71 cases of intertrochanteric fractures with intramedullary fixation by proximal femoral nailing from July 2022 to January 2023. Closed reduction was done in all cases and proximal femoral nail of same manufacturer with helical blade of appropriate size used. Steps of surgery followed were as per established standard described method. Once the patient was pain-free and comfortable, postoperative CT of pelvis and knee joint was done and compared for rotational alignment against the normal opposite side. Measurement was done by technique described by Jeanmart L et al. The rotational difference of <100 in comparison to the normal side was considered as grade I malrotation, 100- 150 as grade II malrotation and >150 as grade III malrotation.

Data was entered in Microsoft excel and analyzed using IBM SPSS Statistics for Windows, Version 20.0. Armonk, NY: IBM Corp. IBM Corp. Categorical variables were expressed as frequency (percentage) and continues variables were expressed in mean and standard deviation. Comparison of mean age and injury to surgery interval across the grade was done using independent t- test. Association of categorical variables like Gender, Side, Mode and Type of deformity with the grades were done using Fisher's exact test. Association of AO classification with grades was done using Pearson Chi-square test. For all these statistical interpretations, p<0.05 was considered the threshold for statistical significance

**Sample size:** According to study conducted by Rajendra Annappa et al1 titled Rotational Malalignment after Intramedullary Fixation of Trochanteric Fractures (<https://doi.org/107860/JCDR/2018/34130.12357>)

24.3% of study population had grade III malrotation after intramedullary fixation of trochanteric fractures.

$$\text{Sample size } N = \frac{Z_{\alpha}^2 P(1-P)}{d^2}$$

$$P = 24.3$$

$$Z_{\alpha} = 1.96$$

$$d = \text{Absolute error} = 10$$

$$N = \frac{Z_{\alpha}^2 P(1-P)}{d^2} = \frac{1.96^2 \times 24.3 \times (100 - 24.3)}{10^2} = 70.6 \approx 71$$

Hence the minimum sample size required would be 71

### Inclusion Criteria

- Patients with isolated trochanteric fractures of femur treated with proximal femoral nailing

### Exclusion Criteria

- Patients who are not willing for CT study
- Pregnant patients with trochanteric fractures fixed with intramedullary nailing
- Patients who sustained pathological fractures of trochanteric region
- Patients with previous femoral neck or shaft fractures
- Patients with fractures of the contralateral femur
- Patients with open fracture of femur

### Methodology

Prospective study would be conducted incorporating all those patients satisfying the inclusion and exclusion criteria. Preoperative x ray of the fractured femur would be used to classify the fracture according to the AO classification. During surgery all patients would be secured on a fracture table in supine position and fracture would be fixed using proximal femoral nail.

Using image intensifier fluoroscopic images of normal hip and knee at same rotation of the C-arm would be obtained and saved which could be used as a reference. Normal anteversion of the hip would be determined which would help in assessing rotational alignment. Anteversion is the angle difference between the true lateral view of hip and knee. Fracture would be reduced initially by traction along the longitudinal axis which could distract the fragments and correct length and then by internal rotation. Once the fracture is provisionally reduced anteroposterior and lateral views would be taken. In antero-posterior view, reduction of medial cortex and in lateral view, reduction of anterior cortex would be assessed. Fractured extremity would be placed in a boot with hip in 20-30 degrees of flexion. Any adjustments required for improving reduction would be made by increasing or decreasing traction or altering abduction/adduction and internal/external rotation. Thorough evaluation of images would be done to avoid the common malalignments: varus deformity, posterior sag and excessive internal rotation. Varus deformity when present would be corrected by abducting the limb. Posterior sagging of the distal fragment which is the sagittal plane deformity would be corrected by applying anterior force to the posterior distal fragment before completing the reduction with traction and internal rotation.

Closed reduction would be attempted in all cases and proximal femoral nail would be used for fixation. Steps of surgery would be followed as per established standard described methods. Patient would be mobilized on the day after surgery with quadriceps exercises and weight bearing as tolerable. Once the patient was pain-free and comfortable postoperative CT of pelvis and knee joint would be done and compared for rotational alignment against the normal opposite side. CT is considered highly accurate method with good reliability and position of the patient does not influence its accuracy. Measurement would be done by technique described by Jeanmart L et al., by determining the angle between the line tangential to femoral condyles and a line drawn through the axis of femoral neck. Malrotation is described as difference in angle between operated and normal side. To rule out any inaccuracy in the CT measurements, all CT images would be measured twice by 2 observers: a radiologist, and an orthopaedic surgeon. The average of these 4 separate measurements would be used in this study. A decrease or increase in the angle on the fractured side means increased external rotation or increased internal rotation of the distal femoral fragment respectively.

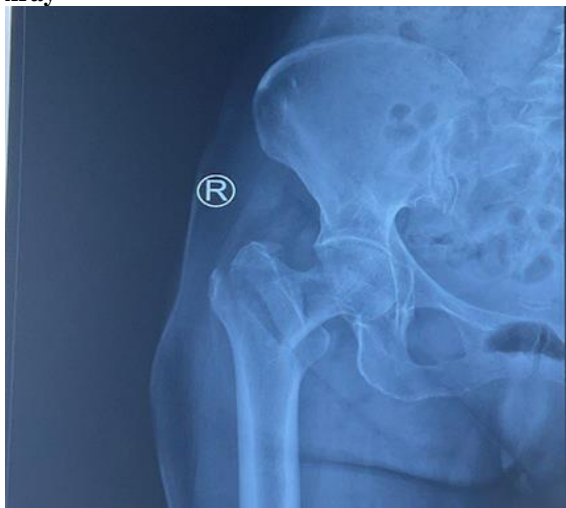#### Ethical Consideration

The study was conducted after obtaining the ethical clearance from the Ethical Committee of Government Medical College, Kottayam and Department of Orthopedics, Government Medical college, Kottayam. Informed written consent was obtained from the cases in the study.

## RESULTS

#### Clinical photographs

##### Group A1AO intertrochanteric fracture pre op xray



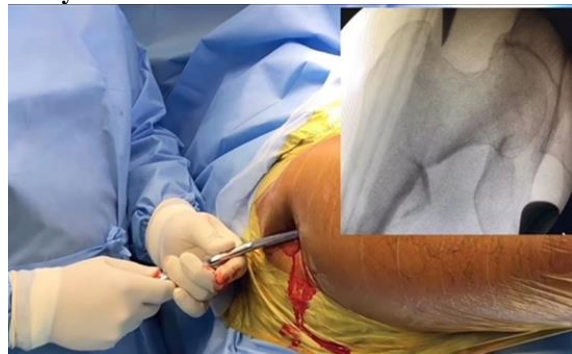There were totally 71 patients included in the study. The mean age of the study population was 65.54. Out of the 71 patients 36(50.7%) were males and 35(49.3%) females. Mode of the injury was slip and fall in 58 patients (81.7%) and road traffic accident in

13 patients (18.3%). 36 (50.7%) patients had left sided fracture and 35 (49.3%) had right sided fracture. The AO/ OTA classification was used for the fracture classification. 34 patients (47.9%) belonged to A1, 21 patients (29.6%) belonged to A2, and 16 patients (22.5%) belonged to A3 of AO/ OTA classification. The mean anteversion on the normal side was 15.76 degrees and that on the fixation side was 19.87. The mean rotational malalignment was 12.18 degrees. 49 patients (69%) had internal rotation deformity and 22 (31%) had external rotation deformity. Grade III malrotation was seen in 15 cases. There were 8 cases with age less than 50 years, and among them 2 had rotational malalignment of more than 15 degrees, and in both cases the fracture type was A3.

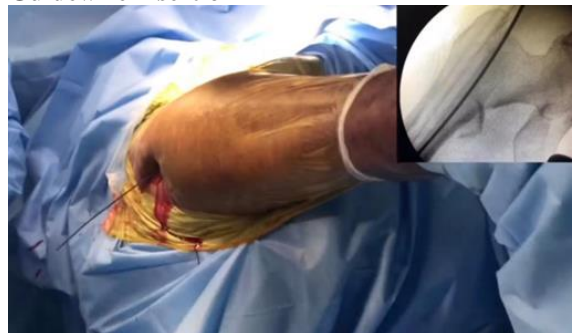#### Patient positioning and c arm orientation



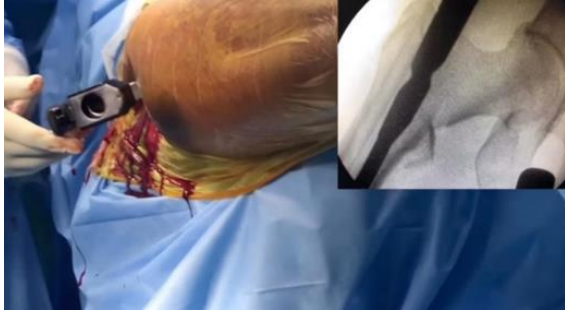#### Entry with bone awl



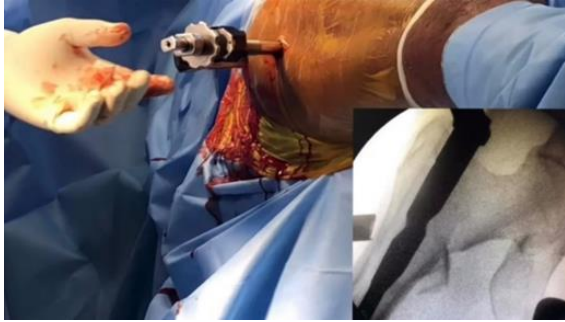
#### Guidewire insertion



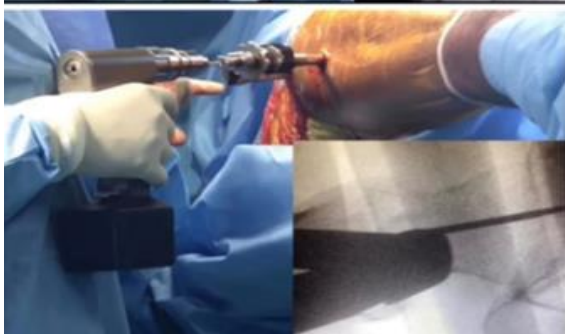
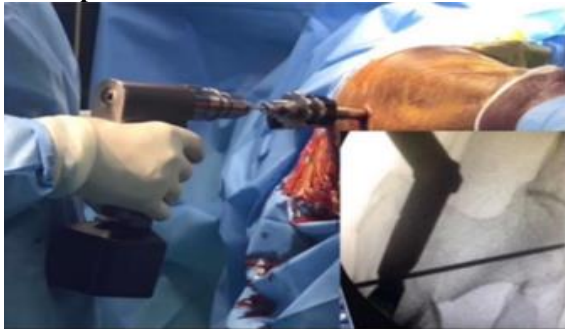
**Nail insertion**



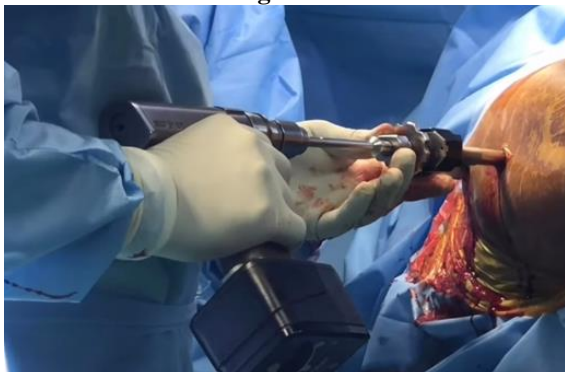
**Trocar and sleeve insertion**



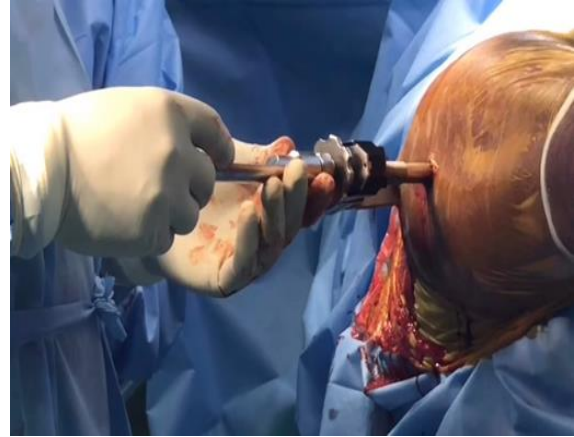**Guide pin insertion**



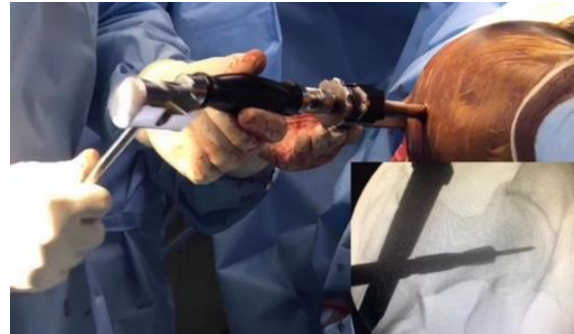
**Outer cortex breaching**



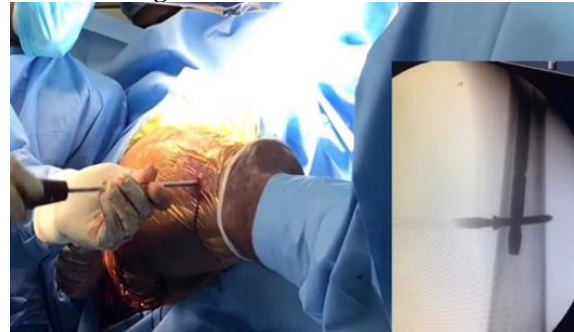**Measurement of helical blade length by gauge**



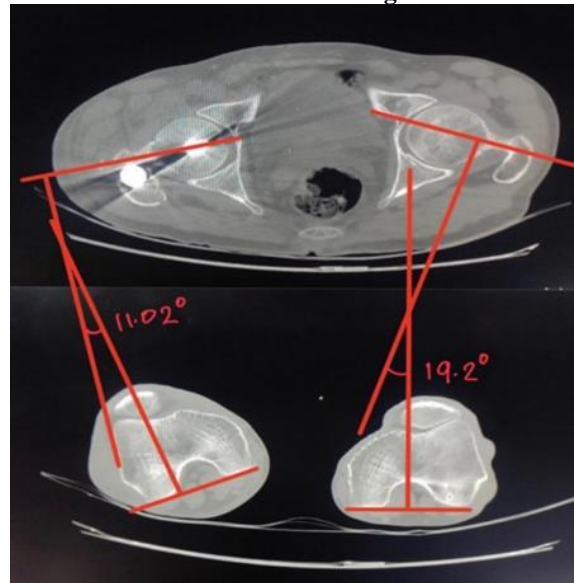
**Insertion of helical blade**



**Distal locking**



**Measurement of rotational malalignment from CT**



**Table 1: description of study population.**

Variables	Levels	Frequency	Percent
Age	≤ 50	8	11.3
	51- 60	6	8.5
	61- 70	33	46.5
	71- 80	24	33.7
Gender	Male	36	50.7
	Female	35	49.3
Side	Right	35	49.3
	Left	36	50.7
Mode	Fall	58	81.7
	RTA	13	18.3
AO classification	A1	34	47.9
	A2	21	29.6
	A3	16	22.5
Grade of malrotation	< 10 degree	23	32.4
	10 - 15 degree	33	46.5
	> 15 degree	15	21.1
Type of deformity	Internal rotation	49	69.0
	External rotation	22	31.0

**Table 2: distribution of cases among different age groups**

Age Group	Frequency	Percentage
≤ 50	8	11.3
51-60	6	8.5
61-70	33	46.5
71-80	24	33.7

**Table 3: gender distribution**

Gender	Frequency	Percentage
Male	36	50.7
Female	35	49.3

**Table 4: Distribution of side of operation**

Side	Frequency	Percentage
Left	36	50.7
Right	35	49.3

**Table 5: mode of injury**

Mode of Injury	Frequency	Percentage
Slip and fall	58	81.7
Road traffic accident	13	18.3

**Table 6: AO/ OTA classification**

AO/OTA Classification	Frequency	Percentage
A1	34	47.9
A2	21	29.6
A3	16	22.5

**Table 7: grade of malrotation**

Grade Of Malrotation	Frequency	Percentage
< 10 degree	23	32.4
10 - 15 degree	33	46.5
> 15 degree	15	21.1

**Table 8: type of rotational deformity**

Type of Deformity	Frequency	Percentage
Internal rotation	49	69.0
External rotation	22	31.0

**Table 9: association of various variables to grades of malrotation**

Variables	Levels	Grade of Malrotation		$\chi^2$	P value
		Grade I & II	Grade III		
Gender	Male	28 (77.8)	8 (22.2)	0.053	1
	Female	28 (80.0)	7 (20.0)		
Side	Right	28 (80.0)	7 (20.0)	0.053	1
	Left	28 (77.8)	8 (22.2)		
Mode	Fall	45 (77.6)	13 (22.4)	0.32	0.72

	RTA	11 (84.6)	2 (15.4)		
AO classification#	A1	33 (97.1)	1 (2.9)	18.68	<0.001*
	A2	16 (76.2)	5 (23.8)		
	A3	7 (43.8)	9 (56.2)		
Type of deformity	Internal rotation	38 (77.6)	11 (22.4)	0.17	0.76
	External rotation	18 (81.8)	4 (18.2)		
*P value<0.05 is considered statistically significant Fisher's exact test #Pearson Chi-square test.					

**Table 10: descriptive statistics**

Variables	N	Minimum	Maximum	Mean	Std. Deviation
Age	71	45	80	66.24	9.22
Ante version of normal side (degree)	71	7.68	38.00	15.76	6.83
Ante version of fixation side (degree)	71	9.16	45.62	19.87	7.24
Rotational malalignment (degree)	71	5.12	22.00	12.18	3.88

**Table 11: distribution of grades of malrotation among different age groups**

Age groups	Grades of malrotation		
	Grade 1	Grade 2	Grade 3
≤ 50	3	3	2
51- 60	3	3	0
61-70	11	16	6
71- 80	7	10	7

**Table 12: distribution of grades of malrotation among gender**

Gender	Male			Female		
	I	II	III	I	II	III
Grade of malrotation						
Frequency	11	17	8	12	16	7
Percentage among the gender group	30.6	47.2	22.2	34.3	45.7	20.0

**Table 13: distribution of grades of malrotation among side**

Side	Left			Right		
	I	II	III	I	II	III
Grade of malrotation						
Frequency	11	17	8	12	16	7
Percentage among different sides	30.6	47.2	22.2	34.3	45.7	20.0

**Table 14: distribution of grades of malrotation among modes of injury**

Mode of Injury	Fall			RTA		
	I	II	III	I	II	III
Grade of malrotation						
Frequency	19	26	13	4	7	2
% among different modes of injury	32.8	44.8	22.4	30.8	53.8	15.4

**Table 15: distribution of grades of malrotation among AO/OTA classification**

AO Classification	A1			A2			A3		
	I	II	III	I	II	III	I	II	III
Grade of malrotation									
Frequency	16	17	1	5	11	5	2	5	9
% among each subgroup of AO classification	47.1	50.0	2.9	23.8	52.4	23.8	12.5	31.3	56.2

**Table 16: distribution according to types of rotational deformity**

Type of Deformity	Internal Rotation			External Rotation		
	I	II	III	I	II	III
Grade of deformity						
Frequency	16	22	11	7	11	4
% among each type of deformity	32.7	44.9	22.4	31.8	50.0	18.2

**Table 17: Comparison of Mean Age and Injury to Surgery Interval among the Grades of Malrotation.**

Variables	Grade of malrotation	N	Mean (S.D)	P Value
Age	Grade I & II	56	65.59 (9.07)	0.254
	Grade III	15	68.67 (9.69)	
Injury surgery interval (days)	Grade I & II	56	5.00 (1.26)	0.532
	Grade III	15	5.33 (1.92)	

P value <0.05 is considered statistically significant.  
Independent t- test.

**Table 18: Comparison of post operative torsional deformities with other studies**

Study	Total number of cases	Grade III malrotation	Internal rotation	External rotation
Ramanoudjame M et al.	40	16 (40.0%)	14 (35.0%)	2 (5.0%)
Kim TY et al.	109	28 (25.7%)	19 (17.4%)	9 (8.3%)
Rajendra Annappa et al.	70	17 (24.3%)	11 (15.7%)	6 (8.6%)
Present study	71	15 (21.1%)	11 (15.7%)	4 (5.6%)

## DISCUSSION

Rotational malalignment is an underrecognized complication of intra medullary nailing. According to literature the incidence ranges from 17% to 35%. This suggests that every third nailing may be in malrotation.<sup>[5]</sup> CT scan guided assessment has the best accuracy to detect this abnormality.<sup>[6-11]</sup> The CT scan guided technique was described by Jeanmart et al. They measured the angle between the axis of femoral neck and posterior femoral condylar line.<sup>[9]</sup> Difference between both lower limbs was considered as rotational malalignment. This technique is considered the gold standard for measurement of rotational malalignment.<sup>[7]</sup> Bråten et al defined rotational difference between 10° to 14° as “possible torsional deformities” and more than 15° as “true rotational deformity”.<sup>[11]</sup> Jaarsma and Pavkis concluded that the value is clinically significant if difference exceeds more than 15 degrees.<sup>[7]</sup>

Rotational malalignment can be measured by physical examination, radiography, ultrasonography and CT. Measurements of anteversion routinely by CT are considered highly accurate. A precise line should be drawn in the center of femoral neck on a CT image which often is the reason for inaccurate measurement. This can be done by CT images with multiple slices and superimposition of slices and precisely drawing the line along the middle of the femoral neck. The accuracy can also be improved by taking the average of more measurements. High incidence of rotational malalignment has been reported after intramedullary fixation of femur shaft fractures in CT studies. Significant malrotation of  $\geq 15^\circ$  has been reported as between 20 to 30%. Ramanoudjame M et al,<sup>[10]</sup> have reported torsional malalignment postoperatively to be as high as 40% and there was no difference between different types of osteosynthesis. Kim TY et al,<sup>[12]</sup> in their study found postoperative torsional deformity in 25.7% after internal fixation of intertrochanteric fractures and identified unstable fractures and a delayed operative time as the major factors. They suggested that unstable fractures when reduced with too much of internal rotation of distal fragment, caused malalignment. In the present study when two-part fractures (31A1) were compared with fractures with communication (31A2 and 31A3) p-value was found to be statistically significant.

Based on the present results, there is a need to achieve adequate intraoperative reduction and prevention of this complication. Authors were of the consensus that methods which can assess anteversion accurately intraoperatively should solve this problem.

Techniques have been described for clinical and radiological evaluation of rotational alignment during operation. In ‘hip rotation test’, the rotation of hip is compared with that of contralateral side. The cortices of the proximal and distal fragments appear to have different thickness in case of torsional deformity, described as ‘diameter difference sign’. In ‘lesser trochanter shape sign’, the size of the lesser trochanter of the injured side is compared with the normal side. The amount of lesser trochanter visible intraoperatively in C-arm posterior-anterior image can be used to estimate rotation. It shows a small area of the lesser trochanter in internal rotation and a larger area in external rotation of the proximal part of the femur. This knowledge helps to obtain the neutral position of the proximal fragment of the fracture during surgery. Reproducing the profile of the lesser trochanter of the unaffected side increases the accuracy of reduction. This can be done easily in femoral shaft fractures but recent advances in computer navigated systems allow a precise reduction of fractures. These are not regularly used in trauma surgeries because of their complexity, the high expense and increased surgical time. Wilharm A et al., in their study on femoral shaft fractures reported a setting up time for the system average  $33 \pm 11.5$  minutes and additional fluoroscopy time of  $36 \pm 22$  seconds was needed to obtain reference X-rays and to verify pin placement. The differences between anteversion assessed intraoperatively by the navigation system and torsional assessment with a postoperative CT were on average  $5.4 \pm 3.5^\circ$ . There are no studies with this system in intertrochanteric fractures. Long-term clinical consequences of rotational deformities after trochanteric fixation are not known. Kim TY et al,<sup>[12]</sup> in their study recorded VAS scores, functional consequences and recorded complication rates of 10.7% in malalignment group and 14.8% in control group. Authors did not observe any statistically significant difference between the groups in clinical outcomes at the end of 1 year. The clinical and functional follow-up should have been correlated with torsional malalignment. Many studies are available for diaphyseal fractures but trochanteric fractures are different from diaphyseal fractures. The mean age, bone quality, mechanism of injuries and comorbidities differ in both groups. The demographic variables and functional expectations vary in these cases.<sup>[13-20]</sup> Torsional malalignment may not significantly affect the clinical results in internal fixation of trochanteric fractures. When deformities are less than 15 degrees patients have fewer complaints and less functional limitations. Rotational deformities are compensated well and tolerated by

patients rarely requiring any intervention. Persisting pain in hip and knee with restriction of movements may cause functional impairment. Degenerative arthritis of knee and hip are noted long-term complications with rotational deformities which also indicates that torsional deformity may aggravate pre-existing degenerative joint diseases in age group where trochanteric fractures are common. Further studies are required to confirm this issue. In young patients, deformities may require surgical correction for those involved in demanding activities such as labour and sports persons. Grade of malrotation determines clinical outcomes. Patients with increased postoperative external rotation perform poorly compared to those with internal rotational deformity, who compensate well and have fewer symptoms. This can be explained by increased retroversion of femoral neck when patient compensates for external rotation.<sup>[21-27]</sup>

## CONCLUSION

When intertrochanteric fractures were treated by internal fixation with PFNA2, rotational malalignments were frequently seen. Grade III malrotation was seen in 21.1% of the cases. As fracture severity increased as in group A3 of AO classification, the chance of higher malrotation also increased. Efforts should be made to avoid rotational malalignment intra operatively. Using C arm to compare the profile of the lesser trochanter of the affected and unaffected side is a good way to control the rotation of the femur. Computer assisted fluoroscopy is a promising technique.

## REFERENCES

- H Kesmezacar T Ogut M G Bilgili S Gokay Y Tenekecioglu Treatment of intertrochanteric femur fractures in elderly patients: internal fixation or hemiarthroplasty *Acta Orthop Traumatol Turc* 2005;39:428-794
- B Aros AN Tosteson DJ Gottlieb KJ Koval Is a sliding hip screw or im nail the preferred implant for intertrochanteric fracture fixation? *Clin Orthop Relat Res* 2008;466:1128-732
- F Fogagnolo M Kfuri CAJ Paccola Intramedullary fixation of pertrochanteric hip fractures with the short AO-ASIF proximal femoral nail *Arch Orthop Trauma Surg* 2004;124:1317
- JD Lindsey JC Krieg Femoral malrotation following intramedullary nail fixation *J Am Acad Orthop Surg* 2011;19:11726
- T Hüfner M Citak EM Suero B Miller D Kendoff C Krettek Femoral malrotation after unreamed intramedullary nailing: an evaluation of influencing operative factors *J Orthop Trauma* 2011;25:422-47
- Annappa R, Mittal H, Kamath SU, Rai S, Suresh PK, Mohammed N. Rotational Malalignment after Intramedullary Fixation of Trochanteric Fractures. *Journal of clinical diagnosis and Research*. 2018; 12(12):RC05-RC08. <https://www.doi.org/10.7860/JCDR/2018/34130/12357>.
- RL Jaarsma DF Pakvis N Verdonschot J Biert AV Kampen Rotational malalignment after intramedullary nailing of femoral fractures *J Orthop Trauma* 2004;18:740-39
- P Tornetta G Ritz A Kantor Femoral torsion after interlocked nailing of unstable femoral fractures *J Trauma* 1995;38:221-39
- L Jeanmart AL Baert A Wackenheim M Osteaux D Balériaux Atlas of Pathological Computer Tomography: Computer Tomography of Neck, Chest, Spine and Limbs Springer-Verlag Heidelberg 1983
- M Ramanoudjame P Guillon C Dauzac C Meunier JM Carcopino CT evaluation of torsional malalignment after intertrochanteric fracture fixation *Orthop Traumatol Surg Res* 2010;96:884-88
- M Bråten T Terjesen I Rossvoll Femoral anteversion in normal adults: ultrasound measurements in 50 men and 50 women *Acta Orthop Scand* 1992;63:129-32
- TY Kim YB Lee JD Chang SS Lee JH Yoo KJ Chung Torsional malalignment, how much significant in the trochanteric fractures? *Injury* 2015;46:1121-6200
- FT Hoaglund WD Low Anatomy of the femoral neck and head, with comparative data from Caucasians and Hong Kong Chinese *Clin Orthop Relat Res* 1980;152:106
- S Decker EM Suero N Hawi CW Müller C Krettek M Citak The physiological range of femoral antetorsion *Skeletal Radiol* 2013;42:1115-015
- Malér J, Džupa V, Buk M, Michna M, Marvan J, Skála-Rosenbaum J. CT analysis of femoral malrotation after intramedullary nailing of trochanteric fractures. *Arch Orthop Trauma Surg*. 2021 Apr 21. doi: 10.1007/s00402-021-03902-3. Epub ahead of print. PMID: 33881592.
- Abubeih, H., Farouk, O., Abdelnasser, M. K., Eisa, A. A., Said, G. Z., & El-Adly, W. (2018). Femoral malalignment after gamma nail insertion in the lateral decubitus position. *SICOT-J*, 4, 34. <https://doi.org/10.1051/sicotj/2018033>.
- Karaman O, Ayhan E, Kesmezacar H, Seker A, Unlu MC, Aydingoz O. Rotational malalignment after closed intramedullary nailing of femoral shaft fractures and its influence on daily life. *Eur J Orthop Surg Traumatol*. 2014 Oct;24(7):1243-7. doi: 10.1007/s00590-013-1289-8. Epub 2013 Aug 11. PMID: 23934503.
- Mosa, E., Mohamed, M., Sleem, A., El-Azab, H. (2021). CT Evaluation of Rotational Malalignment after Intertrochanteric Fracture Fixation. *The Egyptian Journal of Hospital Medicine*, 84(1), 2554-2558. doi: 10.21608/ejhm.2021.188551.
- Sharma, Y., Mugdum, G., & Prabhakara, A. (2017). Rotational malalignment after closed intramedullary nailing of femoral shaft fractures and its influence on functional outcome. *International Journal of Research in Medical Sciences*, 4(7), 2802-2808. doi: <http://dx.doi.org/10.18203/2320-6012.ijrms20161954>.
- Sathy A, Barnwell JC, Shahrestani SN, Moore D. Reliable Method for Avoiding Malrotation Deformity After Intramedullary Nailing of Comminuted Femur Fractures: Clinical Validation of a Previously Described Technique. *J Orthop Trauma*. 2017 Apr;31(4):e121-e126. doi: 10.1097/BOT.0000000000000767. PMID: 28328732.
- Russell TA, Mir HR, Stoneback J, Cohen J, Downs B. Avoidance of malreduction of proximal femoral shaft fractures with the use of a minimally invasive nail insertion technique (MINIT). *J Orthop Trauma*. 2008 Jul;22(6):391-8. doi: 10.1097/BOT.0b013e31817713fe. PMID: 18594303.
- Liodakis E, Kenaway M, Petri M, Zümrüt A, Hawi N, Krettek C, Citak M. Factors influencing neck anteversion during femoral nailing: a retrospective analysis of 220 torsion-difference CTs. *Injury*. 2011 Nov;42(11):1342-5. doi: 10.1016/j.injury.2011.06.004. Epub 2011 Jun 25. PMID: 21704996.
- Berk T, Halvachizadeh S, Martin DP, Hierholzer C, Müller D, Pfeifer R, Jukema GN, Gueorguiev B, Pape HC. Trochanteric fracture pattern is associated with increased risk for nonunion independent of open or closed reduction technique. *BMC Geriatr*. 2022 Dec 22;22(1):990. doi: 10.1186/s12877-022-03694-0. PMID: 36544094; PMCID: PMC9773584.
- Yeganeh A, Taghavi R, Moghtadaei M. Comparing the Intramedullary Nailing Method Versus Dynamic Hip Screw in Treatment of Unstable Intertrochanteric Fractures. *Med Arch*. 2016 Feb;70(1):53-6. doi: 10.5455/medarch.2016.70.53-56. Epub 2016 Jan 31. PMID: 26980933; PMCID: PMC4779359.
- Yang AL, Mao W, Wu JG, He YQ, Ni HF, Li HL, Dong YH. When to Reduce and Fix Displaced Lesser Trochanter in Treatment of Trochanteric Fracture: A Systematic Review. *Front Surg*. 2022 Mar 25;9:855851. doi: 10.3389/fsurg.2022.855851. PMID: 35402493; PMCID: PMC8992837.
- Diaz AR, Navas PZ. Risk factors for trochanteric and femoral neck fracture. *Rev Esp Cir Ortop Traumatol (Engl Ed)*. 2018 Mar-Apr;62(2):134-141. English, Spanish. doi: 10.1016/j.recot.2017.09.002. Epub 2018 Feb 21. PMID: 29429857.
- Jonnes C, Sm S, Najimudeen S. Type II Intertrochanteric Fractures: Proximal Femoral Nailing (PFN) Versus Dynamic Hip Screw (DHS). *Arch Bone Jt Surg*. 2016 Jan;4(1):23-8. PMID: 26894214; PMCID: PMC4733231.